

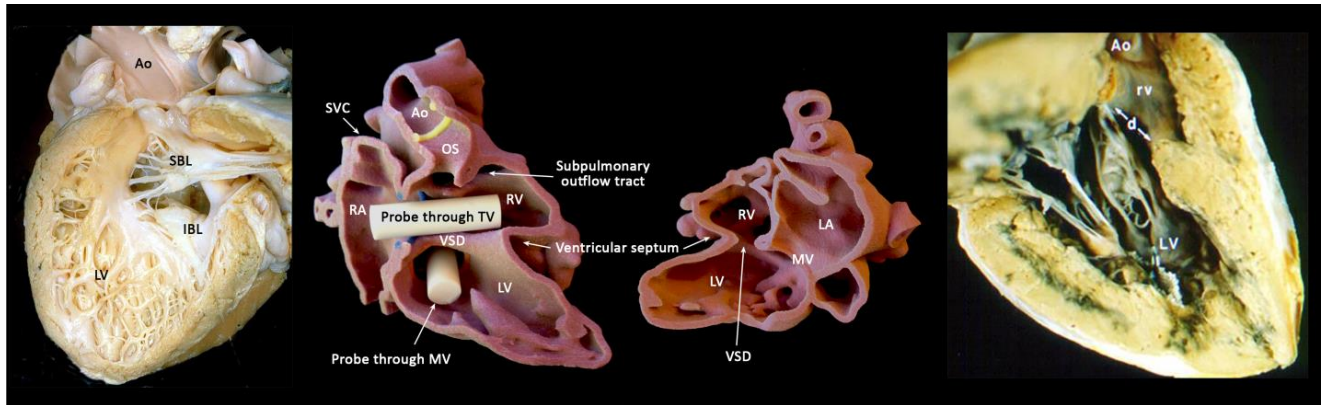
The 2nd Contemporary Morphology Course with Specimens and 3D Print Models
CONGENITAL HEART DISEASES IN YOUR HANDS

♥ Abnormalities of the Atrioventricular Junction ♥

December 6-7, 2019

Peter Gilgan Centre for Research and Learning (PGCRL)

Hospital for Sick Children, Toronto, Canada



HANDS-ON SESSIONS

CASES LIST

CASES LIST: SESSION 1 (1/4)

ATRIOVENTRICULAR SEPTAL DEFECTS AND RELATED CONDITIONS (A)

Case #	Primary diagnosis	Associated findings	Findings of interest
368	AVSD with partitioned AV orifices and interventricular shunt.	<ul style="list-style-type: none"> • Narrow LVOT. • Tubular hypoplasia and coarctation of aorta. • Ligated PDA. 	
621	AVSD with partitioned AV orifices and interatrial shunt		
643	AVSD with common AV orifice, and interatrial interventricular shunts.	<ul style="list-style-type: none"> • Subaortic membranous ridge 	
657	AVSD with partitioned AV orifices and interventricular shunt	<ul style="list-style-type: none"> • Narrow LVOT • Hypoplastic aortic arch 	
664	AVSD with common AV valve orifice, and interatrial and interventricular shunts.	<ul style="list-style-type: none"> • Rastelli A anatomy of anterior bridging leaflet. • Overriding aortic valve. • Chordal insertion of AV valve to LVOT 	Interesting cut from behind showing LVOT and bridging leaflets very well.
695	AVSD with partitioned AV orifices and interventricular shunt	<ul style="list-style-type: none"> • LVOT obstruction due to so-called anteroseptal twist. 	Mechanism of LVOT obstruction
719	AVSD with partitioned AV valve orifice and interatrial shunt. Severe hypoplasia of left side.	<ul style="list-style-type: none"> • Severe LVOT narrowing 	
1241	Perimembranous VSD with inlet extension	<ul style="list-style-type: none"> • Fenestrated fossa ovalis • Perimembranous VSD extending toward the inlet of the right ventricle 	VSD involves the posterior limb of the trabecula septomarginalis and extends toward the inlet along the septal leaflet of the tricuspid valve. Note that the VSD is below and posterior to the insertion of the medial papillary muscle of Lancisi. The tricuspid mitral valves are in direct contact through the VSD.

1250	AVSD with partitioned AV orifices and small interventricular shunt	<ul style="list-style-type: none"> • Secundum ASD 	Small premium ASD
1251	AVSD without interatrial component	<ul style="list-style-type: none"> • Secundum ASDs (multiple fenestrations in the fossa ovalis) • Level of shunt only at interventricular level 	Atrioventricular valve leaflets are attached to the lower margin of the defective atrial septum, leaving the AVSD exclusively between the ventricles. Inlet-outlet disproportion of the left ventricle.
1673	Muscular inlet VSD	<ul style="list-style-type: none"> • VSD involving the septum behind the septal leaflet of the tricuspid valve • Tubular hypoplasia of the aortic arch and isthmus • Patent ductus arteriosus 	In contrast to perimembranous inlet VSD in which the TV and MV are in direct contact through the VSD, there is muscle rim between the VSD margin and the TV and MV attachments.

CASES LIST: SESSION 1 (2/4)

ATRIOVENTRICULAR SEPTAL DEFECTS AND RELATED CONDITIONS (B)

Case #	Primary diagnosis	Associated findings	Findings of interest
649	AVSD with common AV orifice, and interatrial interventricular shunts.	<ul style="list-style-type: none"> • Malalignment of ventricular septum in relation to atrial septum causing double inlet LV connection and double outlet right atrium. 	Posterior insertion of ventricular septum is displaced rightward in relation to the crux cordis.
650	AVSD with partitioned AV valve orifices and interatrial shunt		Classic premium ASD
651	AVSD with common AV valve orifice, and interatrial and interventricular shunts.	<ul style="list-style-type: none"> • Unusually prominent papillary muscle supporting right AV valve overlying the AVSD. 	
655	AVSD with TOF	<ul style="list-style-type: none"> • AVSD extending to the aortic valve annulus. 	Leftward and anterior malalignment of outlet septum with significant pulmonary outflow tract obstruction. Compare this case with #659.
659	AVSD with common AV valve orifice, and interatrial and interventricular shunts.	<ul style="list-style-type: none"> • Chordal attachment in LVOT below aortic valve. • AVSD extending to the aortic valve annulus. 	Leftward and anterior malalignment of outlet septum without significant pulmonary outflow tract obstruction. Compare this case with #659.
712	AVSD with common AV orifice. Interatrial and interventricular shunt	<ul style="list-style-type: none"> • Unbalanced AVSD with small left atrium and ventricle. 	Small interventricular communication through interchordal spaces below anterior bridging leaflet
713	AVSD with DORV	<ul style="list-style-type: none"> • AVSD remote from semilunar valves. • Left BT shunt. 	Although AVSD is aligned with aortic outflow tract, the AVSD does not appear bafflable to aorta.

1270	AVSD with partitioned AV orifices and interventricular shunt	<ul style="list-style-type: none"> • S/P PA banding • Severe biventricular hypertrophy. • Double orifice right AV valve. • Prominent papillary muscles of right AV valve with short chords. • Divided RV cavity. 	Double orifice right AV valve, one opening to posterior inferior inlet and the other opening to outflow tract.
1285	AVSD with common AV orifice with interventricular shunt and no/minimal interventricular shunt		
2403	AVSD with double inlet RV and DORV	<ul style="list-style-type: none"> • Common atrium. • Small LV on the left posterior corner of ventricular mass. • S/P DKS anastomosis. 	

ATRIOVENTRICULAR SEPTAL DEFECTS (3D PRINT MODELS)

Case #	Primary diagnosis	Associated findings	Findings of interest
AVSD1	AVSD with interatrial and interventricular shunts	<ul style="list-style-type: none"> • Large AVSD divided into interatrial and interventricular components by the anterior and posterior bridging leaflets • Right aortic arch with aberrant left subclavian artery 	Rastelli type B arrangement of anterior bridging leaflet of common atrioventricular valve. Anterosuperior displacement (unwedged position) of aortic valve with large distance between aortic valve and crux cordis. Short inlet and long outlet of the ventricles.
AVSD2	AVSD with tetralogy of Fallot	<ul style="list-style-type: none"> • AVSD, divided into interatrial and interventricular components by the bridging leaflets • AVSD extending toward the outlet to aortic valve annulus • Leftward and anterior malalignment of outlet septum causing severe subpulmonary obstruction 	Rastelli type C arrangement of anterior bridging leaflet of common atrioventricular valve. Anterosuperior displacement (unwedged position) of aortic valve with large distance between aortic valve and crux cordis. Short inlet and long outlet of the ventricles.

CASES LIST: SESSION 1 (3/4)

EBSTEIN ANOMALY OF TRICUSPID VALVE (A)

<input type="checkbox"/>	Specimen: 1441	Categories: Ebstein's anomaly
Pathology	<ul style="list-style-type: none"> • Ebstein's anomaly of dysplastic tricuspid valve. 	
Findings	<ul style="list-style-type: none"> • Dysplastic tricuspid valve • Displaced attachment of septal leaflet • Severely dysplastic large anterior and posterior leaflets of tricuspid valve, directly attached to the free wall of the right ventricle (yellow arrows in right panel). • Small right ventricular cavity • Muscular VSD 	
<input type="checkbox"/>	Specimen: 1517	Categories: Ebstein's anomaly
Pathology	<ul style="list-style-type: none"> • Ebstein's anomaly of tricuspid valve 	
Findings	<ul style="list-style-type: none"> • Displaced attachment of dysplastic septal leaflet. • Minor displacement of relatively large posterior leaflet. Only the far posterior part of the posterior leaflet shows displaced attachment (yellow arrows in right panel). • Large anterior leaflet • Partial fusion between anterior and posterior leaflets 	
<input type="checkbox"/>	Specimen: 1526	Categories: Dysplastic valves
Pathology	<ul style="list-style-type: none"> • Dysplastic tricuspid valve without displaced attachment 	
Findings	<ul style="list-style-type: none"> • Dysplastic tricuspid valve leaflets with rolled-up edges. • Direct insertion of anterior and posterior leaflets to anterior papillary muscle. 	
<input type="checkbox"/>	Specimen: 1527	Categories: Ebstein's anomaly
Pathology	<ul style="list-style-type: none"> • Ebstein's anomaly of tricuspid valve 	
Findings	<ul style="list-style-type: none"> • Displaced attachment of septal leaflet (marked by red dotted line on the right panel photo) in relation to tricuspid valve annulus (marked by white dotted line) • Large anterior and posterior leaflets are fused and inserts to the anterior papillary muscle (asterisk) through short chords. • Right atrial dilatation • Right ventricular dilatation and mildly dilated left ventricle 	

<input type="checkbox"/>	Specimen: 1528	Categories: Ebstein's anomaly
Pathology	<ul style="list-style-type: none"> • Ebstein's anomaly of tricuspid valve with pulmonary valve stenosis 	
Findings	<ul style="list-style-type: none"> • Severely attenuated septal leaflet of tricuspid valve • Pulmonary valve stenosis • Right atrial dilatation • Dilated functional right ventricle with thin wall. 	

<input type="checkbox"/>	Specimen: 1529	Categories: Dysplastic valves
Pathology	<ul style="list-style-type: none"> • Dysplastic tricuspid and mitral valves 	
Findings	<ul style="list-style-type: none"> • Thick and dysplastic tricuspid and mitral valve leaflets • No displaced leaflet attachment of tricuspid valve • Dilated right and left atria • Dilated and hypertrophied right ventricle • Mildly thick semilunar valve leaflets • Patent foramen ovale 	

<input type="checkbox"/>	Specimen: 1531	Categories: Ebstein's anomaly
Pathology	<ul style="list-style-type: none"> • Ebstein's anomaly with small muscular VSD 	
Findings	<ul style="list-style-type: none"> • Apically displaced attachment of dysplastic septal leaflet and medial aspect of posterior leaflet • Normal attachment of mildly dysplastic sail-like anterior leaflet and adjacent part of posterior leaflet. • Short chords inserting to anterior papillary muscle of tricuspid valve • Atrial septal defect 	

<input type="checkbox"/>	Specimen: 1534	Categories: Dysplastic valves
Pathology	<ul style="list-style-type: none"> • Dysplastic tricuspid valve 	
Findings	<ul style="list-style-type: none"> • Moderately severe dysplasia of anterior leaflet and mildly dysplastic septal and posterior leaflets of tricuspid valve • Mildly displaced attachment of septal leaflet toward the apex • Pulmonary vein stenosis, stented 	

DOUBLE ORIFICE TRICUSPID VALVE

<input type="checkbox"/>	Specimen: 0604	Categories: VSD / Dual Orifice TV
Pathology	<ul style="list-style-type: none">• Muscular VSD involving the apical trabecular part of the septum• Coarctation of aorta• Double orifice tricuspid valve	
Findings	<ul style="list-style-type: none">• VSD in apical trabecular septum posterior to trabecula septomarginalis• The tricuspid valve orifice is divided into anterior (TV orifice 1) and posterior orifice (TV orifice 2). A kind of papillary muscle arcade is formed below the connecting tongue of the valve leaflet tissue between the two orifices.	

CASES LIST: SESSION 1 (4/4)

EBSTEIN ANOMALY OF TRICUSPID VALVE (A)

<input type="checkbox"/>	Specimen: 1050	Categories: Ebstein's anomaly
Pathology	<ul style="list-style-type: none"> • Stenotic Ebstein's anomaly of tricuspid valve 	
Findings	<ul style="list-style-type: none"> • Displaced attachment of markedly deficient septal and posterior leaflets. Muscularized septal leaflet. Fused septal and posterior leaflet was dissected. Green and yellow dotted lines indicate cut margins of the fused septal and anterior leaflets. In lower panel, the dissected fused leaflets are approximated together. • Large anterior leaflet showing normal attachment • Fusion of anterior leaflet with displaced posterior and septal leaflets to form a tricuspid sac. No boundaries between the fused valve leaflets. A probe is placed through the stenotic tricuspid valve orifice in left lower panel and on the ventricular aspect of the anterior leaflet in right lower panel. Note the small size of the valve orifice. • Dilated right ventricular outflow tract. Endocardial fibroelastosis of the atrialized part of the right ventricle with a irregular patch of fibrous tissue tag on the ventricular septum near tricuspid valve orifice. . • Large atrialized right ventricle. Patent foramen ovale 	
<input type="checkbox"/>	Specimen: 1520	Categories: Ebstein's anomaly
Pathology	<ul style="list-style-type: none"> • Severely stenotic Ebstein's anomaly of tricuspid valve 	
Findings	<ul style="list-style-type: none"> • Marked displaced attachment of septal and posterior leaflets with fusion • Severely dysplastic anterior leaflet is the only functioning part of the tricuspid valve. • Large atrialized part of the right ventricle showing endocardial fibrosis • Functioning part of RV consisting of small outflow component of the right ventricle 	
<input type="checkbox"/>	Specimen: 1521	Categories: Ebstein's anomaly
Pathology	<ul style="list-style-type: none"> • Stenotic Ebstein's anomaly of tricuspid valve with pulmonary atresia. S/P Repair attempt 	
Findings	<ul style="list-style-type: none"> • Displaced attachment of deficient septal and posterior leaflets with rolled margins • Large sail-like terior leaflet, not displaced. • Fusion between displaced septal and posterior leaflets and non-displaced anterior leaflet forming a stenotic sac in the right ventricle. No identifiable boundaries between the leaflets. Green and yellow dotted lines indicate cut edges of the fused anterior and posterior leaflets. • Atretic pulmonary valve • Marked dilatation of right atrium. Patent foramen ovale. Tiny fenestrations in the lower part of the fossa ovalis. • Right ventricular hypertrophy 	

<input type="checkbox"/>	Specimen: 1525	Categories: Ebstein's anomaly
Pathology	<ul style="list-style-type: none"> • Stenotic Ebstein's anomaly of severely deficient tricuspid valve leaflets 	
Findings	<ul style="list-style-type: none"> • Severely vestigial septal leaflet of tricuspid valve firmly attached to the septum and inferior free wall. • Dysplastic anterior leaflet and anterior part of posterior leaflet with normal annular attachment. • Free edge of fused anterior and posterior leaflets attach directly to the right ventricular free wall (yellow arrows in both panels). • Leaflets fuse directly to apical myocardium leaving no ventricular space in apical region. • Right atrial dilatation 	

<input type="checkbox"/>	Specimen: 1530	Categories: Ebstein's anomaly
Pathology	<ul style="list-style-type: none"> • Stenotic Ebstein's anomaly 	
Findings	<ul style="list-style-type: none"> • Apically displaced attachment of dysplastic septal leaflet. Muscularized posterior leaflet. • Fused anterior, septal and posterior leaflets forming pouch-like sac along the septum. A part of the pouch behind the fused leaflets is marked by an asterisk. • Cut edges of fused leaflets are approximated in lower panel. Note small size of major orifice of the tricuspid valve and a tiny additional holes in the fused leaflets. 	

<input type="checkbox"/>	Specimen: 1533	Categories: Ebstein's anomaly
Pathology	<ul style="list-style-type: none"> • Ebstein's anomaly. 	
Findings	<ul style="list-style-type: none"> • Mildly displaced attachment of septal and posterior leaflets of tricuspid valve. • Patent foramen ovale 	

<input type="checkbox"/>	Specimen: 1742	Categories: Ebstein's anomaly
Pathology	<ul style="list-style-type: none"> • Ebstein's anomaly with very thin atrialized part of right ventricle 	
Findings	<ul style="list-style-type: none"> • Markedly displaced attachment of small dysplastic septal and posterior leaflets • Very thin wall of the atrialized part of the right ventricular inlet transilluminated from outside (left lower panel) and from inside (right lower panel). Anatomical atrioventricular junction is demarcated by the coronary artery branch. • Dilated right atrium. Atrial septal defect. • Dilated right ventricle. 	

<input type="checkbox"/>	Specimen: 1769	Categories: Ebstein's anomaly
Pathology	<ul style="list-style-type: none"> • Ebstein's anomaly with hypoplastic septal leaflet and severely attenuated posterior leaflet. 	
Findings	<ul style="list-style-type: none"> • Displaced attachment of septal and posterior leaflets of tricuspid valve (marked by red dotted line. Tricuspid valve annulus is marked by white dotted line).. • Normal attachment of anterior leaflet of tricuspid valve • Hypoplastic septal leaflet. Severely attenuated posterior leaflet. • Large membranous septum as shown in transilluminated photo in left lower panel. 	

<input type="checkbox"/>	Specimen: 2408	Categories: Ebstein's anomaly
Pathology	<ul style="list-style-type: none"> • Explanted stenotic Ebstein's anomaly. S/P Tricuspid valve plasty 	
Findings	<ul style="list-style-type: none"> • Displaced attachment of septal and posterior leaflets of tricuspid valve. • Normal attachment of anterior leaflet of tricuspid valve • Fusion of most parts of the free edges of the leaflets leaving a few small openings, forming a so-called tricuspid valve sac • Small openings in the fused valve leaflets are the only egressing routes for right atrial flow to the right ventricle. 	

CASES LIST: SESSIONS 2 (1/4)

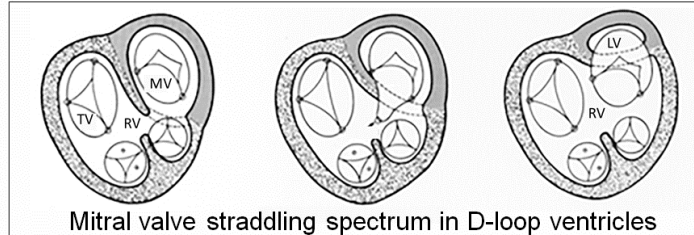
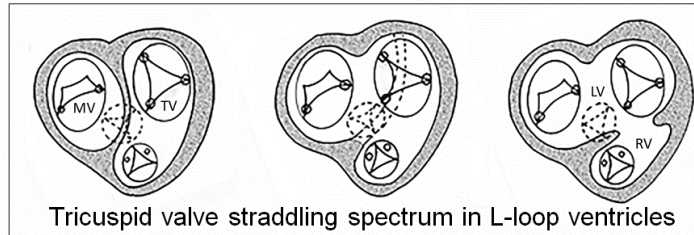
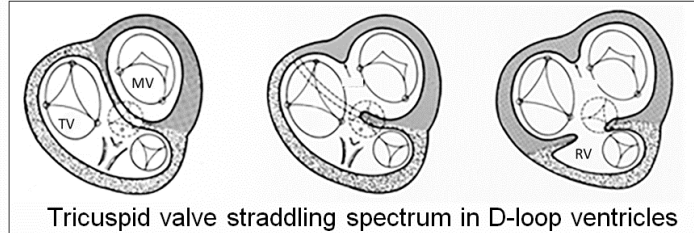
MITRAL VALVE PATHOLOGIES

Case #	Primary diagnosis	Associated findings
2196	Mitral stenosis and perimembranous VSD	<ul style="list-style-type: none"> ● Thick dysplastic mitral valve leaflets with short chords ● Endocardial fibroelastosis involving a part of LV ● Mildly hypoplastic distal aortic arch ● Large patent ductus arteriosus ● Mildly dysplastic tricuspid valve ● Perimembranous VSD extending toward the RV inlet
2197	Mitral stenosis	<ul style="list-style-type: none"> ● Dysplastic leaflets doming downward with short chords ● Left atrial dilatation ● Intact atrial septum ● Mildly dysplastic tricuspid valve ● Unusually large anterior papillary muscle of tricuspid valve
2198	Mitral stenosis	<ul style="list-style-type: none"> ● Mildly dysplastic mitral valve leaflets ● Small size of mitral valve leaflets with short chords ● Appearing significantly regurgitant as well as stenotic
2200	Mitral stenosis	<ul style="list-style-type: none"> ● Very thick mitral valve leaflets with no chords ● Mild endocardial fibroelastosis
2201	Shone's complex	<ul style="list-style-type: none"> ● Small patent foramen ovale ● Small left side structures ● Small anterior leaflet of mitral valve directly inserted to papillary muscles
2202	Severe mitral and aortic stenosis	<ul style="list-style-type: none"> ● Small mitral valve with leaflet fusion and thickening ● Deformed, closely spaced and partly fused papillary muscles. No chords ● Endocardial fibroelastosis of LV ● Very thick dysplastic aortic valve leaflets ● Thick subaortic fibrous ridge/membrane ● Poststenotic dilatation of ascending aorta ● Intact atrial septum
2203	Mitral stenosis	<ul style="list-style-type: none"> ● Thick dysplastic mitral valve leaflets with rolled edges ● Small mitral valve orifice ● Dilated left atrium

2204	Severe mitral and aortic stenosis	<ul style="list-style-type: none"> ● Very short, muscularized chords ● Severely stenotic dysplastic aortic valve ● Dilated left atrium with endocardial fibroelastosis
2358	S/P Mitral valve replacement with Starr-Edwards caged ball valve	<ul style="list-style-type: none"> ● Dilated LV with endocardial fibroelastosis
2717	<p>Perimembranous VSD with aortic valve prolapsed and stenosis</p> <p>Described as rheumatic valvular heart disease (Requires clarification)</p>	<ul style="list-style-type: none"> ● Perimembranous VSD ● RV side of the VSD, shrouded by adjacent septal leaflet of tricuspid valve. ● Unusual anterior leaflet of tricuspid valve with direct attachment to the RV wall with only a few attenuated chords ● Prolapse of thickened aortic valve leaflets

CASES LIST: SESSIONS 2 (2/4)

STRADDLING / OVERRIDING TRICUSPID AND MITRAL VALVES



Case #	Primary diagnosis	Associated findings	Findings of interest
567	DIRV and DORV with straddling mitral valve	<ul style="list-style-type: none"> • Small LV at left posterior aspect of large RV • DORV with bilateral infundibulum 	Interventricular septal plane aligned with the interatrial septal plane at crux cordis along the inferior surface of the heart
633	Absent left AV connection with straddling right AV valve	<ul style="list-style-type: none"> • Situs solitus with levocardia • Small RV at superior aspect of large LV (not able to tell whether it is D-looped or L-looped ventricles) • Absent left atrioventricular connection • Straddling right atrioventricular valve • Concordant ventriculoarterial connection with normally related great arteries • Patent ductus arteriosus • Intact atrial septum 	The ventricular septal plane is not aligned with the atrial septal plane and the crux cordis.

635	DORV and discordant AV connection with straddling mitral valve	<ul style="list-style-type: none"> • VSD extending from outlet to inlet. • Rightward malalignment of anterior part of the ventricular septum. • VSD is related to the pulmonary valve. 	<p>The anterior part of the ventricular septum is malaligned rightward in relation to the atrial septal plane. Ventricular septal insertion to crux cordis is maintained.</p> <p>Compare this case with #1040.</p>
660	DILV with straddling left-sided TV	<ul style="list-style-type: none"> • Situs solitus with levocardia • Small RV at left superior aspect of large LV (L-looped ventricles) • Large VSD • Straddling left atrioventricular valve (TV). 	<p>The ventricular septal plane is not aligned with the atrial septal plane. The ventricular septal insertion to the posterior wall is away from the crux cordis.</p>
1040	DORV with straddling mitral valve	<ul style="list-style-type: none"> • VSD extending from outlet to inlet. • Leftward malalignment of anterior part of the ventricular septum. • VSD is related to the pulmonary valve. • Double orifice mitral valve with anterior orifice facing toward the right ventricle. The right ventricular aspect of this mitral valve orifice is shrouded by the hypertrophied muscle bundles. • Prominent subaortic and absent subpulmonary infundibulum. • Atrial septal defect 	<p>The anterior part of the ventricular septum is malaligned leftward in relation to the atrial septa plane. Ventricular septal insertion to crux cordis is maintained. Although the VSD is related pulmonary outflow tract, the ventricular septal anatomy is different from that of classic Taussig-Bing malformation. Malalignment of the anterior aspect of the septum leaves the pulmonary valve in the right ventricle.</p> <p>Compare this case with #635 (mitral valve straddling with AV discordant connection). Also compare this case with #1043 (Classic Taussig-Bing malformation). The VSD appears close to the pulmonary valve in this case. However, the VSD does not involve the outlet part of the septum between the limbs of the trabecula septomarginalis.</p>
1043	DORV with subpulmonary VSD	<ul style="list-style-type: none"> • Perimembranous outlet VSD is cradled by the limbs of the trabecula septomarginalis. • Malaligned outlet septum inserting to right margin of VSD. • Long and narrow subaortic and short subpulmonary infundibulum. • Small aorta and dilated pulmonary artery. 	<p>Classic Taussig-Bing malformation with the VSD involving and confined to outlet part of the septum between the limbs of trabecula septomarginalis.</p>

1251	Inlet VSD with MV abnormality	<ul style="list-style-type: none"> • Perimembranous VSD extending toward the inlet. • Straddling mitral valve without significant malalignment of the atrial and ventricular septal planes • Atrial septal defects • Normal related and connected great arteries 	Quite extensive extension of the VSD toward the inlet with no significant atrioventricular septal malalignment
1638	Straddling TV with RV hypoplasia and TGA	<ul style="list-style-type: none"> • Situs solitus with levocardia • Small RV on the right side of large LV (D-looped ventricles) • Perimembranous VSD with inlet extension • Transposition of the great arteries 	Ventricular septal malalignment with the posterior part of the septum displaced to the right away from the crux cordis
2674	DILV and TGA with straddling left AV valve	<ul style="list-style-type: none"> • Situs solitus with levocardia • Small RV on the left superior aspect of large LV • Straddling of left atrioventricular valve through a large VSD • Transposition of the great arteries 	The ventricular septal plane is not aligned with the atrial septal plane. The ventricular septal insertion to the posterior wall is away from the crux cordis.

CASES LIST: SESSIONS 2 (3/4)

CONGENITALLY CORRECTED TGA –Specimens

Case #	Primary diagnosis	Associated findings	Findings of interest
617	Corrected TGA with Ebstein's anomaly in situs inverses	<ul style="list-style-type: none"> • Situs inversus • AV and VA discordant connections • Medium sized perimembranous VSD below posterior limb of trabecula septomarginalis • Large muscular VSD in anterior part of trabecular septum: Divided into two openings by the preserved part of trabecular septomarginalis • Ebstein's anomaly 	Muscular VSD involves the septum dividing the anterosuperior recess of the left ventricle and upper anterior trabecular part of the right ventricle. Ebstein's malformation involves the septal leaflet and part of the posterior leaflet of the tricuspid valve. The involved septal and posterior leaflets unusually have fare lengths of mobile parts. The leaflets are dysplastic.
1171	Corrected TGA with double orifice TV	<ul style="list-style-type: none"> • Intact ventricular septum • Two sets of equally sized tricuspid valves. 	One opening into inlet and the other opening directly to outlet. The valve opening to inlet shows Ebstein's malformation.
1634	Corrected TGA with Ebstein's malformation	<ul style="list-style-type: none"> • Valvar aortic atresia 	Severely displaced attachment of septal and posterior leaflets of tricuspid valve. Large dysplastic anterior leaflet.
1735	Corrected TGA with Ebstein's malformation and aortic atresia	<ul style="list-style-type: none"> • Severe Ebstein's malformation. Atrietic aortic valve is dissected. • Small ascending aorta. 	The aortic valve atresia may be due to severely reduced flow through the aortic valve in fetal life as a result of severe TR.
1906	Corrected TGA with Ebstein malformation and perimembranous outlet VSD	<ul style="list-style-type: none"> • Aortic arch reconstruction 	Reconstructed aortic arch suggests the original diagnosis of interrupted aortic arch or severe coarctation.
2142	Corrected TGA with Ebstein's malformation	<ul style="list-style-type: none"> • S/P TV replacement 	Small prosthetic valve in left-sided tricuspid valve location. Supernumerary papillary muscles supporting anterior leaflet of mitral valve.
2145	Corrected TGA with perimembranous outlet VSD		
2146	Corrected TGA with	<ul style="list-style-type: none"> • VSD is partly covered by the 	Relatively large atrioventricular

	perimembranous VSD	septal and anterior leaflets of the tricuspid valve. <ul style="list-style-type: none"> • Dysplastic tricuspid valve. • Small PDA 	component of membranous septum
2178	Corrected TGA with VSD	<ul style="list-style-type: none"> • S/P TV replacement 	
2179	Corrected TGA with perimembranous VSD	<ul style="list-style-type: none"> • Mesocardia • Surgical closure of VSD 	
2367	Discordant AV connection with concordant VA connection	<ul style="list-style-type: none"> • Ebstein's malformation • Small RV size and small PA • PDA 	<i>Described as DORV(?) in original description.</i>

CASES LIST: SESSIONS 2 (4/4)

CONGENITALLY CORRECTED TGA - 3D PRINT MODELS

Case #	Primary diagnosis	Associated findings	Findings of interest
TGA 9	Congenitally corrected TGA with intact ventricular septum	<ul style="list-style-type: none"> No subpulmonary infundibulum with mitral-pulmonary fibrous continuity 	Typical great arterial relationship of congenitally corrected TGA with the aorta on the left and anterior to the pulmonary artery.
TGA 10	Congenitally corrected TGA with small perimembranous VSD	<ul style="list-style-type: none"> Mildly narrow LVOT 	Congenitally corrected TGA with the aorta directly anterior to the small pulmonary arterial trunk. Note a small recess of cavity at the anterior superior corner of the LV below the right atrial appendage.
TGA 11	Congenitally corrected TGA with a small perimembranous VSD	<ul style="list-style-type: none"> Mesocardia No outflow tract obstruction 	Typical great arterial relationship of congenitally corrected TGA with the aorta on the left and anterior to the pulmonary artery. Note a small recess of cavity at the anterior superior corner of the LV below the right atrial appendage.
TGA 12	Congenitally corrected TGA with a perimembranous VSD and Ebstein's malformation of tricuspid valve	<ul style="list-style-type: none"> Small right-sided LV and dilated left-sided RV Apically displaced septal and posterior leaflets of tricuspid valve Mild subpulmonary stenosis 	Ebstein anomaly of tricuspid valve with relatively mild apically displaced attachment.
TGA 13	Congenitally corrected TGA with straddling tricuspid valve (valves not shown).	<ul style="list-style-type: none"> S/P Pulmonary artery banding Superinferior relationship of the ventricles 	The inlet ventricular septum is mildly malaligned in relation to the atrial septum with the posterior part of the inlet ventricular septum displaced away from the crux cordis.
TGA 14	Double inlet left ventricle with transposition of the great arteries	<ul style="list-style-type: none"> Small RV located superior and left to large LV Aortic valve located left and anterior to pulmonary valve Mildly restrictive muscular VSD Tubular hypoplasia of the aortic arch 	Severe leftward and superior malalignment of the ventricular septum with the small right ventricle located on the top of the left ventricle. Remnant of inlet ventricular septum called posteromedian muscle ridge seen between the right and left atrioventricular valves.

SickKids 65	Congenitally corrected TGA with a perimembranous VSD and Ebstein's malformation of tricuspid valve	<ul style="list-style-type: none"> • Mesocardia • S/P Starnes' procedure and pulmonary artery banding • Muscular tunnel narrowing of LVOT above the VSD 	Starnes' procedure on the left-sided tricuspid valve resulted in relatively small size of the right ventricle, which is the aim of the procedure to improve the LV geometry by reducing the RV size.
----------------	--	--	--

STRADDLING MITRAL AND TRICUPSID VALVES - 3D PRINT MODELS

Case #	Primary diagnosis	Associated findings	Findings of interest
SickKids 136	Perimembranous inlet and outlet VSD of malalignment type with overriding and straddling tricuspid valve	<ul style="list-style-type: none"> • Severe tubular hypoplasia of distal aortic arch • Small PDA 	The inlet part of the ventricular septum is malaligned rightward and forward in relation to the interatrial septal plane with the posterior part of the ventricular septum not inserting to the crux cordis (the point where the interatrial septum inserts to the posterior atrioventricular groove). The tricuspid valve annulus overrides ventricular septum with its chords inserted to the papillary muscles on both sides of the septum.
TGA 6	Double outlet firth ventricle with subpulmonary VSD	<ul style="list-style-type: none"> • Non-perimembranous VSD involving the outlet component of ventricular septum. • Origin of both arterial trunks from RV through bilateral muscular infundibulum • Narrow subaortic infundibulum • Aortic arch hypoplasia 	The outlet septum is malaligned rightward away from the plane of the rest of the ventricular septum and atrial septum. The outlet septum is oriented parallel to the rest of the ventricular septum within the right ventricle. The VSD is below the pulmonary valve on the left side of the aortic valve. <i>Compare this case with #TGA 7.</i>

TGA 7	VSD involving outlet and inlet with mitral valve straddling and double outlet right ventricle. Subpulmonary location of VSD	<ul style="list-style-type: none"> • Severe subpulmonary stenosis and small pulmonary valve annulus size 	<p>The anterior part of the ventricular septum is malaligned significantly leftward and backward in relation to the interatrial septal plane with the posterior part of the ventricular septum inserted to the crux cordis (the point where the interatrial septum inserts to the posterior atrioventricular groove). The mitral valve consists of three leaflets with the anterior and medial leaflets having chordal insertion to the shared papillary muscle in the right ventricle. Both arterial trunks arise from the right ventricle with the left-sided pulmonary valve and outflow tract related to the VSD.</p> <p><i>Compare this case with #TGA6.</i></p>
-------	---	---	---

CASES LIST: SESSIONS 3 (1/4)

HYPOPLASTIC LEFT HEART SYNDROME AND RELATED CONDITIONS

Case #	Primary diagnosis	Associated findings
18	HLHS with mitral and aortic stenosis	<ul style="list-style-type: none"> ● Intact atrial septum ● Severely thickened mitral valve leaflets, directly attached to anterolateral papillary muscle and short chordal attachment to posteromedial papillary muscle ● Severe EFE of LA and LV ● Dysplastic stenotic aortic valve
24	HLHS with severe mitral and aortic stenosis	<ul style="list-style-type: none"> ● Patent foramen ovale ● Small thickened mitral valve leaflets directly attached to hypoplastic papillary muscles with a few short chords ● Moderate LV hypoplasia with EFE
33	HLHS with severe mitral stenosis and aortic atresia, S/P Norwood operation	<ul style="list-style-type: none"> ● S/P Norwood operation ● Large interatrial defect after atrial septectomy
34	HLHS with mitral and aortic stenosis	<ul style="list-style-type: none"> ● Patent foramen ovale ● Small LA and LV ● Thick mitral valve leaflets directly attached LV free wall with a few short chords ● EFE of LV ● Small unicuspid stenotic aortic valve
52	HLHS with absent left atrioventricular connection and aortic atresia	<ul style="list-style-type: none"> ● Small patent foramen ovale ● No mitral valve tissue ● Slit-like LV ● Large patent ductus arteriosus
85	HLHS with mitral and aortic stenosis	<ul style="list-style-type: none"> ● Large patent foramen ovale ● Small mitral valve with thick leaflets and short chords ● Moderate hypoplasia of LV ● Dysplastic tricuspid aortic valve with stenosis
90	HLHS with mitral stenosis and aortic atresia	<ul style="list-style-type: none"> ● Small patent foramen ovale ● Very small mitral valve with no chords ● Tiny LV cavity size

97	Hypoplasia of left side of the heart with a small perimembranous VSD	<ul style="list-style-type: none"> ● Large patent foramen ovale ● Small size of all left side ● Mildly dysplastic aortic valve ● Patent ductus arteriosus
155	HLHS with mitral stenosis and aortic atresia	<ul style="list-style-type: none"> ● Patent foramen ovale ● Small LA and tiny LV ● Tiny dysplastic mitral valve leaflets ● No obvious EFE ● Patent ductus arteriosus
161	HLHS with mitral stenosis and aortic atresia.	<ul style="list-style-type: none"> ● Small LA and LV ● Severe EFE
172	HLHS with mitral stenosis and aortic atresia	<ul style="list-style-type: none"> ● Patent foramen ovale ● Small LA and LV ● Small dysplastic mitral valve ● Large patent ductus arteriosus
1544	Aortic stenosis	<ul style="list-style-type: none"> ● Severely hypoplastic ascending aorta ● Small aortic arch, larger than ascending aorta suggesting retrograde flow into ascending aorta in fetal life ● Patent foramen ovale ● EFE of LV
1545	HLHS, S/P Norwood operation	<ul style="list-style-type: none"> ● Large interatrial communication after atrial septectomy ● Tiny LV
1731	HLHS with severe mitral stenosis and aortic atresia	<ul style="list-style-type: none"> ● Intact atrial septum (premature closure during fetal life) ● Severe mitral stenosis with mildly dilated left atrium and pulmonary veins ● Tiny LV ● EFE of LA and LV ● Large patent ductus arteriosus

EFE, endocardial fibroelastosis / HLHS, hypoplastic left heart syndrome

CASES LIST: SESSIONS 3 (2/4)

DOUBLE INLET VENTRICLES

Case #	Primary diagnosis	Associated findings	Findings of interest
554	DILV with TGA. Restrictive VSD	<ul style="list-style-type: none"> • Situs solitus with levocardia • Intact atrial septum • Tiny RV directly superior to LV giving rise to small aorta • Pulmonary artery arising from LV. No subpulmonary infundibulum. 	<ul style="list-style-type: none"> • Posteromedian muscle ridge between the right and left atrioventricular valves along the posterior wall of the main chamber of left ventricle • Severely restrictive VSD (so-called button-hole defect) causing severe subaortic stenosis
561	DILV with concordant ventriculoarterial connection	<ul style="list-style-type: none"> • Situs solitus with levocardia • Small RV at right superior aspect of LV giving rise to pulmonary artery • Aorta from LV. No subaortic infundibulum. • Small VSD • Right atrioventricular valve attached to posterior margin of the VSD • S/P right side BT shunt 	<ul style="list-style-type: none"> • Small VSD, shrouded by right atrioventricular valve leaflet, causing severe subpulmonary obstruction. • Posteromedian muscle ridge between the right and left atrioventricular valves along the posterior wall of the main chamber of left ventricle
562	Double inlet and double outlet indeterminate ventricle	<ul style="list-style-type: none"> • Situs solitus with levocardia. • Single ventricular chamber. • Subaortic infundibulum. No subpulmonary infundibulum. • Subaortic stenosis due to hypertrophic outlet septum and chords arising from right atrioventricular valve attached to outlet septum • Aorta, anterior and slightly right to pulmonary artery • Atrial septal defect 	<ul style="list-style-type: none"> • No identifiable rudimentary ventricular chamber • Prominent outlet septum contributing to subaortic stenosis •

567	DIRV and DORV with straddling mitral valve	<ul style="list-style-type: none"> • Situs solitus with levocardia • Straddling mitral valve • Small LV at left posterior aspect of large RV • DORV with bilateral infundibulum 	<ul style="list-style-type: none"> • Interventricular septal plane aligned with the interatrial septal plane at crux cordis along the inferior surface of the heart
1586	DILV with normally related and connected arterial trunks (so-called Holmes heart). Pulmonary atresia	<ul style="list-style-type: none"> • Situs solitus with levocardia • Small RV at right superior aspect of LV • Pulmonary atresia • Small left-sided patent ductus arteriosus 	<ul style="list-style-type: none"> • Posteromedian muscle ridge between the right and left atrioventricular valves along the posterior wall of the main chamber of left ventricle
1587	DILV with normally related and connected arterial trunks (so-called Holmes heart).	<ul style="list-style-type: none"> • Situs solitus with levocardia • Intact atrial septum • Small RV directly superior to LV • Chordal insertion of left atrioventricular valve to VSD margin 	<ul style="list-style-type: none"> • Posteromedian muscle ridge between the right and left atrioventricular valves along the posterior wall of the main chamber of left ventricle
1918	Twisted concordant atrioventricular connections with TGA	<ul style="list-style-type: none"> • Situs solitus with levocardia • RV apex pointing to the left and LV apex pointing to the right • Overriding and straddling mitral valve • Large inlet VSD • Intact atrial septum 	<ul style="list-style-type: none"> • Mildly twisted atrioventricular connection axes. • Tricuspid valve annulus, higher than mitral valve annulus • Aorta, mostly anterior and mildly rightward to pulmonary arterial trunk
2662	DIRV two AVVs stenotic left AVV, LSVC to CS. PAB, two VSDs	<ul style="list-style-type: none"> • Situs solitus with levocardia • Severely hypoplastic left atrium with tiny mitral valve • Patent foramen ovale • Bilateral SVCs • Dilated coronary sinus with a large defect in the party wall between coronary sinus and left atrium • Left side patent ductus arteriosus • S/P pulmonary artery banding 	<ul style="list-style-type: none"> • Tiny mitral valve hiding behind and left-side of large tricuspid valve • Shared orifice of IVC and coronary sinus in the right atrium

2668	Double inlet and double outlet right or left ventricle. Left juxtaposition of the atrial appendages	<ul style="list-style-type: none"> ● Situs solitus, levocardia ● Atrial septal defects ● Dilated coronary sinus. Persistent left SVC, dissected? ● Small ventricular chamber at the right side of the crux cordis ● Double inlet left-sided main ventricular chamber versus biventricular connection with small right-sided ventricle 	<ul style="list-style-type: none"> ● Horizontally located atrial septum due to left juxtaposition of the atrial appendages ● Ventricular morphology is hard to define. By location, the small ventricle appears to be the LV. By trabeculation pattern, the small ventricle appears to be the RV.
2671	DIRV with TGA and pulmonary atresia	<ul style="list-style-type: none"> ● Situs solitus with levocardia ● Tiny LV on the right side of RV ● No main pulmonary artery with confluent branch pulmonary arteries ● Patent ductus arteriosus 	<ul style="list-style-type: none"> ● Rudimentary LV at the corner of crux cordis

CASES LIST: SESSIONS 3 (3/4)

ABSENT RIGHT OR LEFT ATRIOVENTRICULAR CONNECTION

Case #	Primary diagnosis	Associated findings	Findings of interest
945	Imperforate tricuspid valve	<ul style="list-style-type: none"> • Situs solitus with levocardia • D-loop ventricles with small RV • Patent foramen ovale • No identifiable VSD • Concordant VA connection with small pulmonary artery 	Blind ending pouch of atretic tricuspid valve protruding into small RV. Small papillary muscle and chords supporting atretic TV.
990	Absent right AV connection and concordant VA connection with left juxtaposition of the atrial appendages	<ul style="list-style-type: none"> • Situs solitus with mesocardia • D-loop ventricles with tiny RV on the right anterior aspect of large LV • Absent right AV connection • Patent foramen ovale and ASD • Tiny VSD • Concordant VA connection with pulmonary atresia • BT and central shunts 	Left juxtaposition of the atrial appendages with ASDs in the horizontal atrial septum.
991	Absent right AV connection with concordant VA connection	<ul style="list-style-type: none"> • Situs solitus with levocardia • D-loop ventricles with small RV • Absent right AV connection • ASDs • Large VSD immediately below aortic valve • Concordant VA connection with small PA • Left SVC to coronary sinus • Large right side BT shunt 	There is a small dimple at the expected location of the tricuspid valve.
992	Absent right AV connection with discordant VA connection and pulmonary atresia	<ul style="list-style-type: none"> • Situs solitus with levocardia • D-loop ventricles • Absent right AV connection • Patent foramen ovale • VSD with straddling mitral valve • Discordant VA connection • Pulmonary atresia • Patent ductus arteriosus 	Anterior part of the mitral valve straddles into small RV, shrouding the VSD.

1003	Absent right AV connection with concordant VA connection	<ul style="list-style-type: none"> • Situs solitus with levocardia • D-loop ventricles with small RV • Absent right AV connection • Patent foramen ovale • Tiny VSD below aortic valve • Concordant VA connection with small pulmonary artery • Patent ductus arteriosus 	
1583	Absent right AV connection with concordant VA connection	<ul style="list-style-type: none"> • Situs solitus with levocardia • D-loop ventricles with small RV • Absent right AV connection • Patent foramen ovale • Small muscular VSD at some distance from aortic valve • Concordant VA connection 	
1723	Absent left AV connection, single ventricle and aortic atresia	<ul style="list-style-type: none"> • Situs solitus with levocardia • One identifiable ventricle. Possibly L-loop ventricles with extremely hypoplastic RV at left superior aspect of LV • Absent left AV connection • Patent foramen ovale • Large pulmonary artery arising from single ventricle without subpulmonary infundibulum • Tiny aorta connected to anterior superior aspect of ventricular mass in front of dilated pulmonary artery • Large patent ductus arteriosus 	
1728	Absent left AV connection and aortic atresia	<ul style="list-style-type: none"> • Only one large ventricular chamber, identifiable. • Large pulmonary trunk from this ventricle. Atretic aortic valve at left anterior aspect of pulmonary arterial trunk. 	
2210	Absent left AV connection with concordant VA connection	<ul style="list-style-type: none"> • Situs solitus with levocardia • D-loop ventricles with small LV • Absent left AV connection • ASD. Dilated right atrium • Perimembranous outlet VSD 	

		<ul style="list-style-type: none"> • Biventricular origin of aorta without subaortic infundibulum • Pulmonary artery from RV through a prominent infundibulum • Patent ductus arteriosus 	
2211	Absent left AV connection with DORV	<ul style="list-style-type: none"> • Situs solitus with levocardia • D-loop ventricles with tiny LV • Absent left AV connection • Intact atrial septum • Tiny perimembranous VSD close to pulmonary valve • Double outlet right ventricle with subaortic infundibulum and no subpulmonary infundibulum. • Narrow distal aortic arch 	
2218	Absent left AV connection with concordant VA connection	<ul style="list-style-type: none"> • Situs solitus with levocardia • D-loop ventricles with small but sizable LV • Absent left AV connection • Intact atrial septum with aneurysmal fossa ovalis protruding into left atrium • Small left atrium • Two small muscular VSDs involving apical trabecular septum • Small patent aortic valve • Patent ductus arteriosus • Small aortic arch 	Large membranous septum between right atrium and left ventricle

CASES LIST: SESSIONS 3 (4/4)

TWISTED OR CRISSCROSS HEART AND RELATED CONDITIONS

Case #	Primary diagnosis	Associated findings
T-1	Twisted heart with complete transposition of the great arteries	<ul style="list-style-type: none"> ♥ Situs solitus / Levocardia / Left aortic arch ♥ Concordant atrioventricular connection / Discordant ventriculoarterial connection ♥ Superoinferior relationship of the ventricles with the right ventricle on top of the left ventricle ♥ Aorta located anteriorly and slightly leftward relative to the pulmonary arterial trunk ♥ Bilateral subaortic and subpulmonary infundibulum. The subpulmonary infundibulum is short. ♥ Hypoplastic outlet septum, mildly malaligned anteriorly relative to the rest of the ventricular septum. Mild overriding of the pulmonary valve across the VSD ♥ Confluent inlet and outlet VSD at a short distance from the semilunar valves ♥ Tight pulmonary artery banding located close to the pulmonary arterial bifurcation
T-2	Twisted heart with concordant atrioventricular connection and double outlet right ventricle	<ul style="list-style-type: none"> ♥ Situs solitus / Levocardia / Left aortic arch ♥ Concordant atrioventricular connection / Double outlet right ventricle ♥ Superoinferior relationship of the ventricles with the right ventricle above and behind the left ventricle. ♥ Aorta located directly anterior to the pulmonary arterial trunk ♥ Bilateral infundibulum with a long subaortic and a short subpulmonary infundibulum ♥ Subaortic narrowing due to deviated outlet septum ♥ A large inlet VSD remote from the semilunar valves. Mild overriding of the tricuspid annulus across the VSD ♥ Tubular hypoplasia of the aortic arch and coarctation of the aorta with small patent ductus arteriosus

T-3	Mildly twisted atrioventricular connection to superoinferiorly related ventricles with double outlet right ventricle	<ul style="list-style-type: none"> ♥ Situs solitus / Levocardia / Right aortic arch with mirror-image branching ♥ Concordant atrioventricular connection / Double outlet right ventricle ♥ Right ventricle positioned superior and anterior to the left ventricle ♥ Double outlet right ventricle with subaortic and subpulmonary infundibulum ♥ Aorta on the right and anterior to pulmonary arterial trunk ♥ VSD involving mostly the inlet part of the right ventricular aspect of the septum. An additional apical muscular VSD ♥ Left juxtaposition of the atrial appendages
T-4	Twisted heart with congenitally corrected transposition of the great arteries	<ul style="list-style-type: none"> ♥ Situs solitus / Levocardia / Left aortic arch ♥ Discordant atrioventricular connection / Discordant ventriculoarterial connection ♥ Inverted anteroposterior relationship of the ventricles for the given atrioventricular connection with the right ventricle anterior and the left ventricle posterior ♥ Aorta located anteriorly and slightly leftward relative to the pulmonary arterial trunk ♥ Aorta arising from the right ventricle through a muscular infundibulum and pulmonary arterial trunk arising from the left ventricle without muscular infundibulum ♥ Confluent inlet and outlet VSD with its upper margin close to the semilunar valves ♥ Dilated right pulmonary artery
T-5	Twisted heart with congenitally corrected transposition of the great arteries	<ul style="list-style-type: none"> ♥ Situs solitus / Levocardia / Left aortic arch ♥ Discordant atrioventricular connection / Discordant ventriculoarterial connection ♥ Right ventricle, positioned superior and anterior to the Left ventricle ♥ Right and left ventricular apices pointing the opposite directions ♥ Non-parallel, twisted atrioventricular connection axes ♥ Aortic valve located directly anterior to the pulmonary valve ♥ Well-developed subaortic infundibulum. Very short subpulmonary infundibulum ♥ Long and narrow muscular subaortic outflow tract. ♥ Diffusely small aorta with severe tubular hypoplasia of the aortic arch and coarctation of the aorta. A large patent ductus arteriosus ♥ A large VSD between the inlet of the right ventricle and the outlet of the left ventricle.

T-6	Mildly twisted heart with atrioventricular discordant connection, double outlet right ventricle with a subpulmonary VSD, and partial anomalous pulmonary venous connection	<ul style="list-style-type: none"> ♥ Situs solitus / Levocardia / Atrioventricular discordant connection / Double outlet right ventricle ♥ Superior-inferior relationship of the ventricles with mildly twisted atrioventricular connection axes ♥ Aorta located anteriorly and rightward relative to the pulmonary arterial trunk. ♥ Bilateral infundibulum with a long subaortic and short subpulmonary infundibulum ♥ A unrestrictive VSD extending toward the outlet and committed to pulmonary outflow tract ♥ Severe tubular hypoplasia of the aortic arch ♥ Anomalous connection of the left upper pulmonary vein to the left brachiocephalic vein, anomalous connection of the right upper and middle pulmonary veins to the superior vena cava
T-7	Twisted heart with aorta as a single arterial trunk from the right ventricle and pulmonary atresia in situs solitus and dextrocardia	<ul style="list-style-type: none"> ♥ Situs solitus / Dextrocardia / Left aortic arch ♥ Concordant atrioventricular connection / aorta as the single arterial trunk arising from right ventricle ♥ Superior-inferior relationship of the ventricles with the hypoplastic right ventricle on top of the left ventricle ♥ Non-parallel, twisted atrioventricular connection axes: tricuspid valve opening directly forward and mitral valve opening rightward and forward ♥ A large VSD between the inlets of the ventricles. ♥ Small tricuspid valve annulus overriding the ventricular septum through the VSD. ♥ Aorta arising from right ventricle through well-developed subaortic infundibulum ♥ Confluent pulmonary arteries supplied by a large left-side patent ductus arteriosus. No main pulmonary arterial segment.
T-8	Superoinferiorly related ventricles with double outlet right ventricle in situs solitus and dextrocardia	<ul style="list-style-type: none"> ♥ Situs solitus / Dextrocardia / Left aortic arch ♥ Major part of the right atrium positioned superior to the left atrium with juxtaposition of the atrial appendages on the left side ♥ Concordant atrioventricular connection / Double outlet right ventricle ♥ Superior-inferior relationship of the ventricles with the right ventricle superior and posterior to the left ventricle ♥ Parallel atrioventricular connection axes ♥ Both aorta and pulmonary arterial trunk arising from the right ventricle through a longer subaortic infundibulum and a shorter and severely narrowed subpulmonary infundibulum ♥ Ascending aorta positioned leftward and anterior to the pulmonary arterial trunk ♥ A large outlet VSD closer to the aortic valve

T-9	Twisted heart with the left ventricle superiorly located in situs solitus, mesocardia and tetralogy of Fallot	<ul style="list-style-type: none"> ♥ Situs solitus / Mesocardia / Left aortic arch ♥ Protruding heart underneath the deficient anterior chest wall (Figure1) ♥ Right atrial vestibular part elongated in a right-left direction with the tricuspid valve displaced far leftward. Elongated left atrial vestibular part in anteroposterior direction with the mitral valve displaced superiorly. ♥ Large secundum atrial septal defect ♥ Concordant atrioventricular connection with non-parallel atrioventricular connection axes. ♥ Mitral valve positioned superior to the tricuspid valve. Opening axis of the tricuspid valve directed forward and leftward. Opening axis of the mitral valve directed forward and slightly upward. ♥ Left ventricle located anterior and superior to the right ventricle. Right ventricle wrapping around the left ventricle from below and behind. ♥ Concordant ventriculoarterial connection with an exaggerated intertwined relationship between the right and left ventricular outflow tracts and arterial trunks. ♥ A large confluent perimembranous VSD in close proximity to the aortic valve. ♥ Aortic valve located posteriorly and inferiorly relative to the pulmonary valve ♥ Elongated pulmonary trunk.
T-10	So-called topsy-turvy heart with double outlet right ventricle	<ul style="list-style-type: none"> ♥ Situs solitus / Levocardia / Left aortic arch ♥ Unusual superoinferior relationship of the cardiac chambers with the left atrium and left ventricle above and the major part of the right atrium and right ventricle below. ♥ Juxtaposition of the atrial appendages on the right side ♥ Large secundum atrial septal defect ♥ Concordant atrioventricular connection with parallel atrioventricular connection axes ♥ Right ventricular outflow tracts arising from the far posterior aspect of the right ventricle. ♥ Double outlet right ventricle through a muscular infundibulum that is evenly divided into the subaortic and subpulmonary outflow tract ♥ A large confluent VSD that is closer to the subaortic outflow tract ♥ Aortic valve located anterior and slightly to the right of the pulmonary valve ♥ Long ascending aorta and pulmonary arterial trunk taking acutely angulated proximal courses. ♥ Confluent pulmonary arteries with a tortuous patent ductus arteriosus.

T-11	Congenitally corrected transposition of the great arteries with superoinferior ventricles and parallel atrioventricular valves	<ul style="list-style-type: none"> ♥ Situs solitus / Levocardia / Left aortic arch ♥ Atrioventricular discordant connection with parallel axes of mitral and tricuspid valve openings ♥ Superoinferior relationship of the ventricles with the right ventricle located leftward and superior relative to the left ventricle ♥ Small permembranous ventricular septal defect ♥ Long subaortic and short subpulmonary infundibulum ♥ Ascending aorta anterior and slightly left of the pulmonary arterial trunk
T-12	Classic double inlet left ventricle and transposition of the great arteries	<ul style="list-style-type: none"> ♥ Situs solitus / Levocardia / Left aortic arch ♥ Both right and left atria connecting to the main chamber of left ventricular morphology (double inlet left ventricle). Parallel open axes of the right and left atrioventricular valves. ♥ Hypoplastic right ventricle located superior, left ward and slightly posterior to the left ventricle ♥ A large ventricular septal defect. ♥ Pulmonary arterial trunk arising from the left ventricle without a muscular infundibulum. Aorta arising from the right ventricle through a muscular infundibulum ♥ Subpulmonary outflow stenosis and small pulmonary valve annulus